

SYNCHRONIZED RF & HIFEM: FAT HISTOLOGY & SCANNING ELECTRON MICROSCOPY STUDY

SIMULTANEOUS APPLICATION OF HIGH-INTENSITY FOCUSED ELECTROMAGNETIC FIELD AND SYNCHRONIZED RADIOFREQUENCY FOR FAT DISRUPTION: HISTOLOGICAL AND ELECTRON MICROSCOPY PORCINE MODEL STUDY

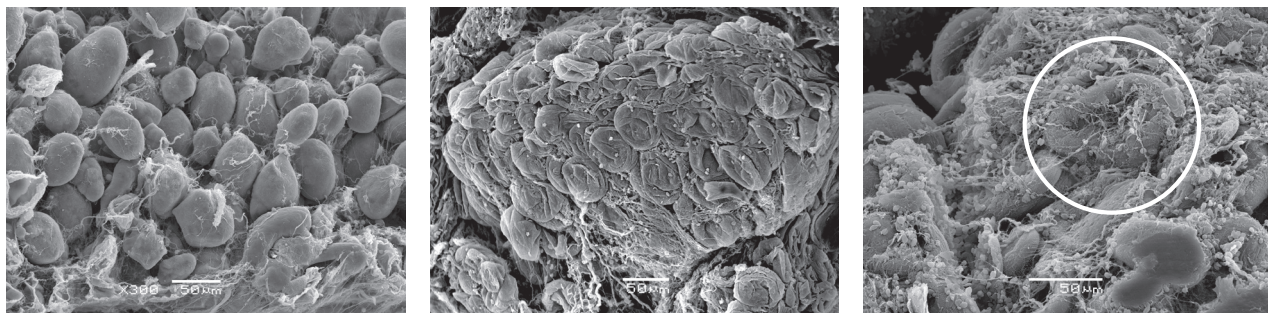Robert A. Weiss MD, FAAD¹, MVDr. Jan Bernardy Ph.D.²,
Prof. MVDr. Frantisek Tichy, CSc³

1. Maryland Laser Skin & Vein Institute, Hunt Valley, MD, USA; 2. Veterinary Research Institute, Brno, CZ
3. Department of Anatomy and Histology, University of Veterinary and Pharmaceutical Sciences Brno, CZ

Published in Dermatologic Surgery journal, June 2021, DOI: 10.1097/DSS.0000000000003091

HIGHLIGHTS

- Both **histology** and **scanning electron microscopy** showed **damaged adipocytes** post-treatment due to apoptosis and lipolysis.
- **Adipocyte size** was **decreased by 31.1%** at 2 weeks post-treatment.
- The **temperature** in fat tissue was maintained **just below 45°C** for the entire treatment.
- **No necrosis** was seen in the tissue.



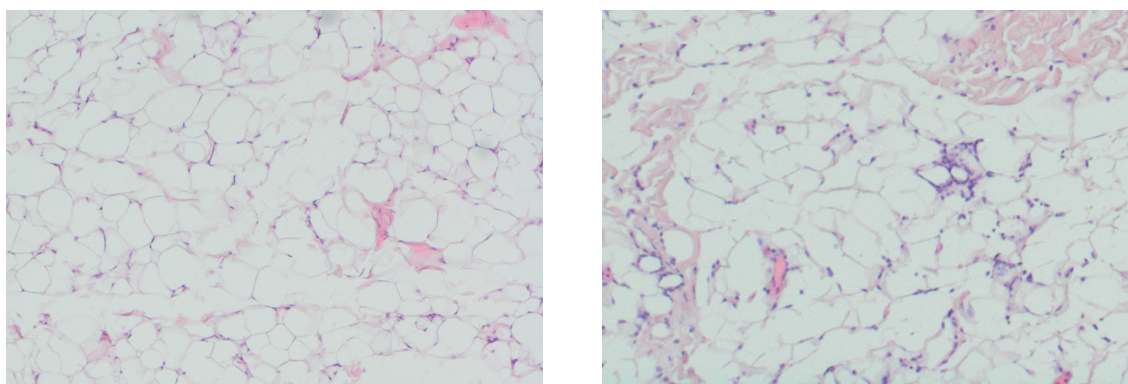
Healthy fat cells with well-defined shape at the baseline (left); shrunk adipocytes with noticeable membrane ruptures occurred at 4 days (center); disrupted adipocytes with extrusion of lipid droplets at two weeks (right)

STUDY DESIGN

- 7 Large White pigs (approximately 6 months old).
- All animals received three 30-minute treatments applied to abdomen.
- Biopsies of fat tissue (including control specimens) were collected at baseline, 4 days, 2 weeks, 1 month and 2 months post treatment.
- Histologies were evaluated under the light and scanning electron microscope.

CONCLUSION

- The procedure elevates the **temperature** in subcutaneous fat to levels **necessary for apoptosis induction**.
- **Efficacy** of the procedure for **adipocytes deletion** was documented in **252** analyzed tissue slices.
- Mild inflammatory response was present to promote the **apoptotic death cells removal**.
- **No burns, necrosis or other serious adverse events** were observed.



Baseline histology (left) showed adipocytes without any damage. At 2 weeks (right), flattened adipocytes with delaminated membranes are seen along with immune cells clearing the damaged tissue.